

Breakout Session 1: Track B

Detection and Localization of Prostate Cancer: A Structured Multi-Scale Multiparametric MRI Database for AI/ML Research

Dr. Kyung Sung (Moderator)

Associate Professor, University of California, Los Angeles

Detection and Localization of Prostate Cancer: A Structured Multi-Scale Multiparametric MRI Database for AI/ML Research



David Geffen
School of Medicine

UCLA

Health System

Kyung Sung, Ph.D.

Associate Professor

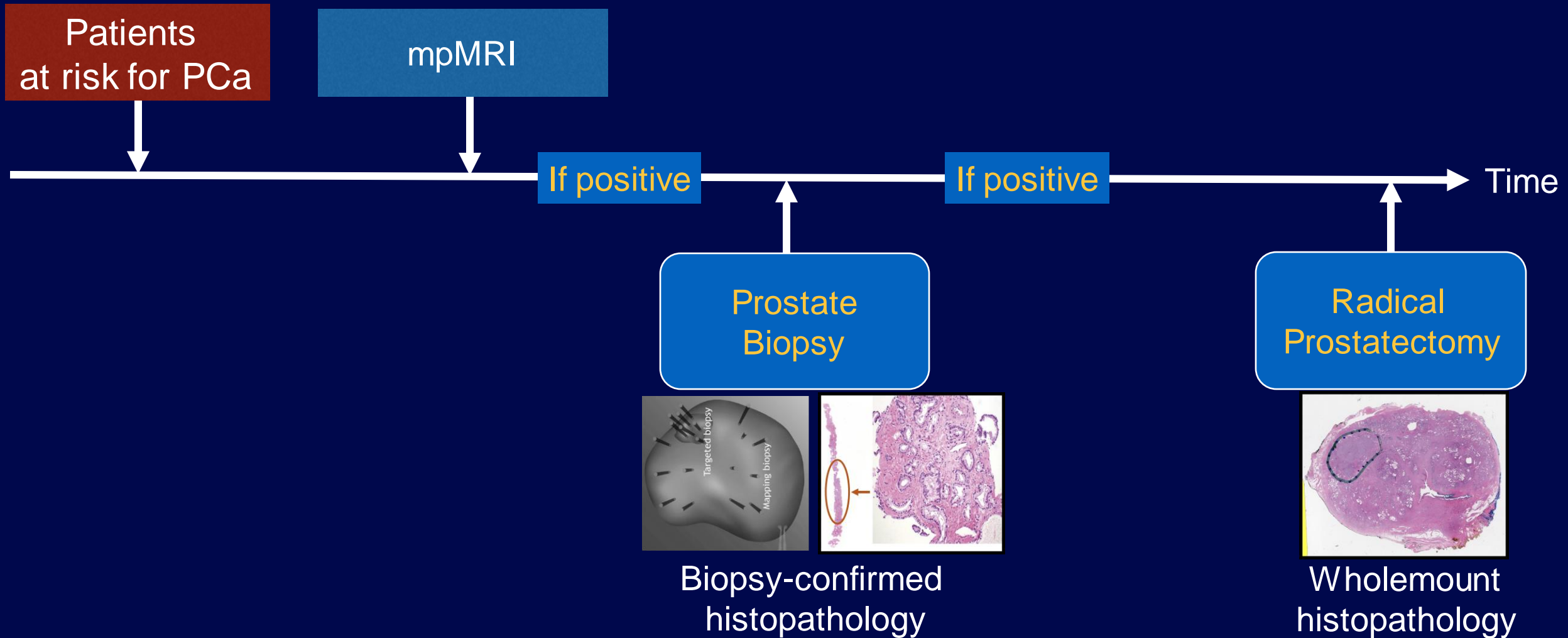
Magnetic Resonance Research Labs (MRRL)

Department of Radiological Sciences,

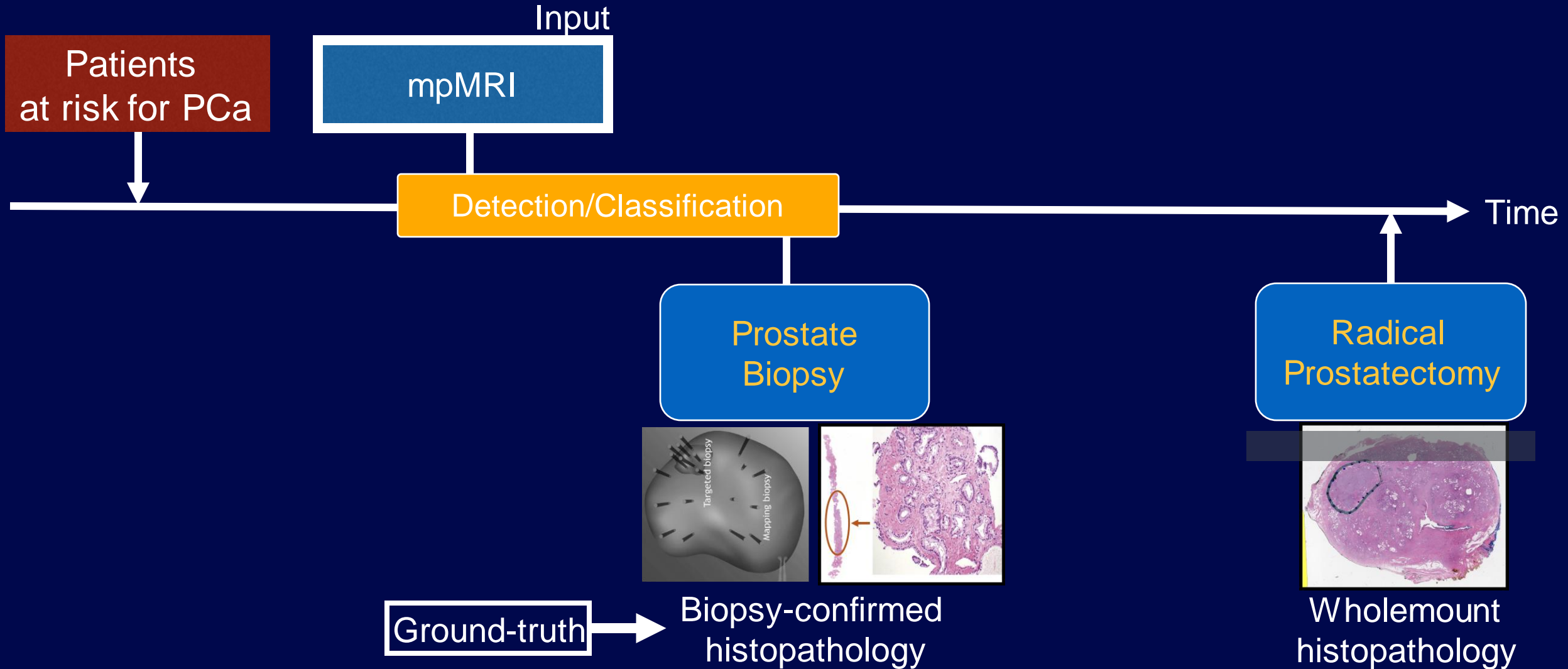
Bioengineering, and Physics & Biology in Medicine (PBM)

University of California, Los Angeles

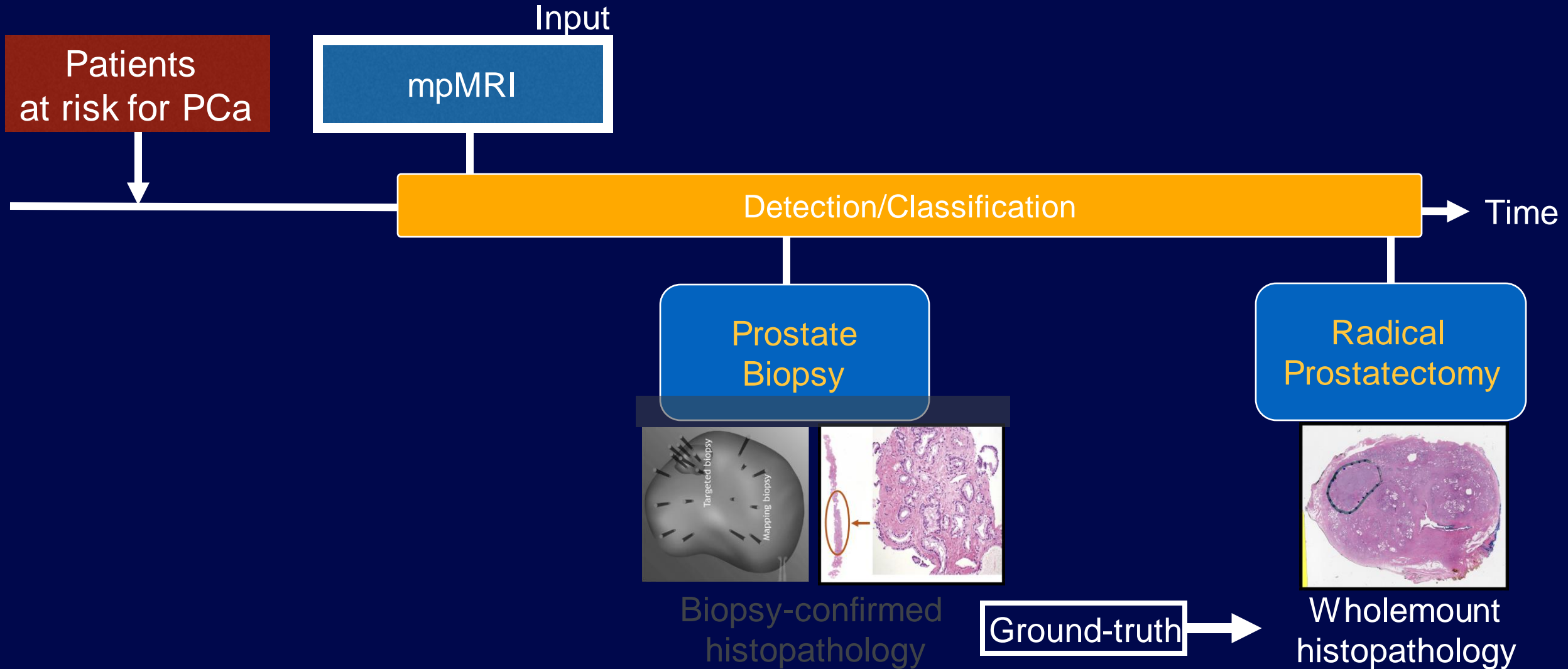
Prostate Cancer Diagnosis and Treatment



AI/ML Models for Prostate Cancer Detection

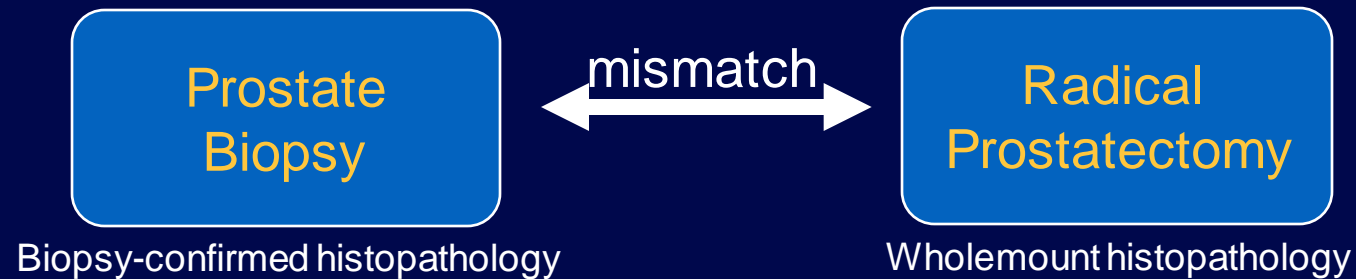


AI/ML Models for Prostate Cancer Detection



Introduction

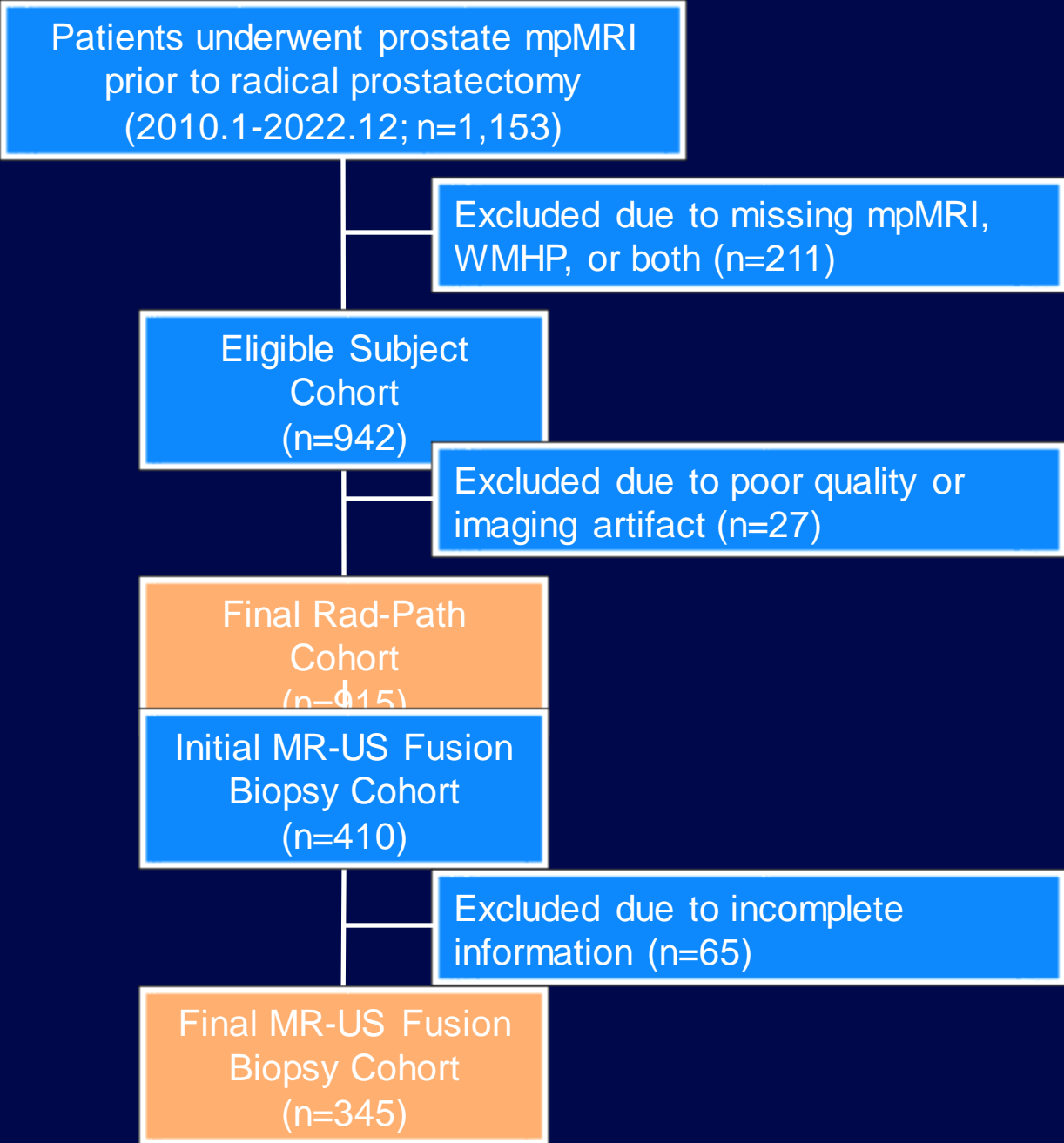
- Studies have shown that more than 30% of cases of indolent PCa (iPCa) at biopsy are upgraded to clinically significant (csPCa), while more than 25% of csPCa at biopsy are downgraded to iPCa following analysis of whole-mount histopathology (WMHP)



- Discrepancies between biopsy-confirmed histopathology (BCHP) and WMHP highlight the importance of a structured multi-scale mpMRI database for AI/ML research

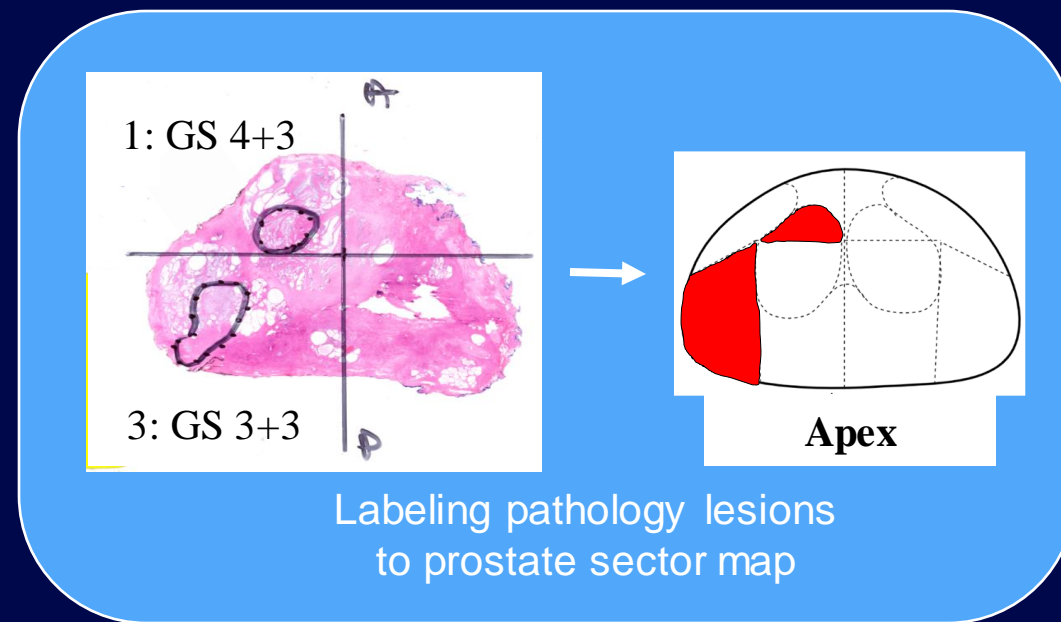
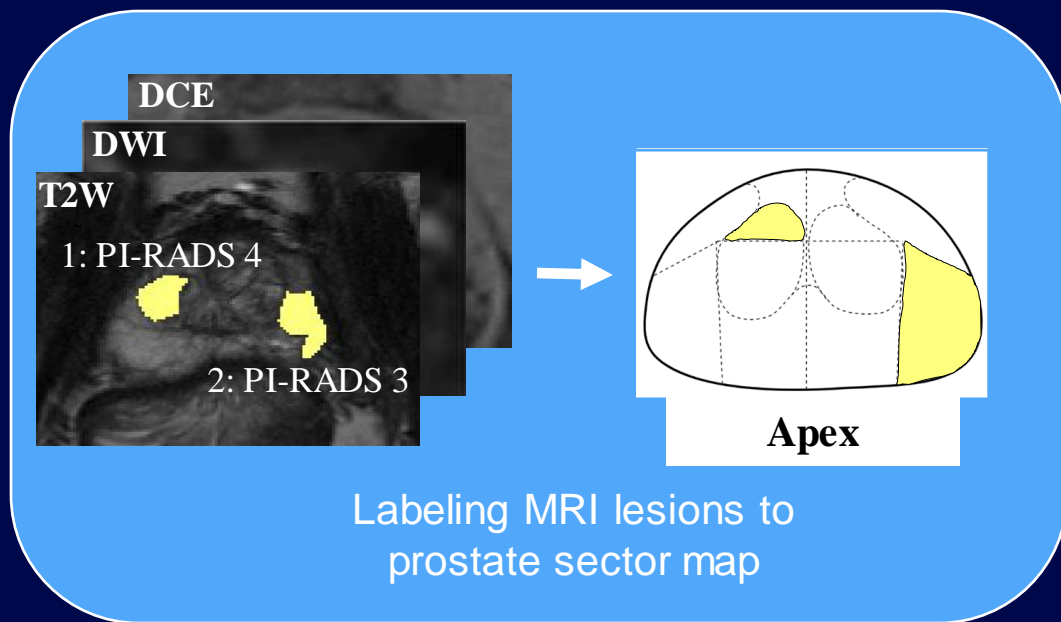
Purpose

- Build a multi-scale dataset with available mpMRI annotations for analysis
- Build a data subset of patients with csPCa who underwent both MR-US fusion biopsy and RALP and have available BCHP and WMHP to:
 - Assess associations between mpMRI parameters and upgrading from BCHP to WMHP
 - Reduce the diagnosis of indolent PCa and improve the diagnosis of csPCa
- QC all lesion contours on mpMRI using the standardized prostate model to verify accurate spatial information to improve ongoing AI/ML development

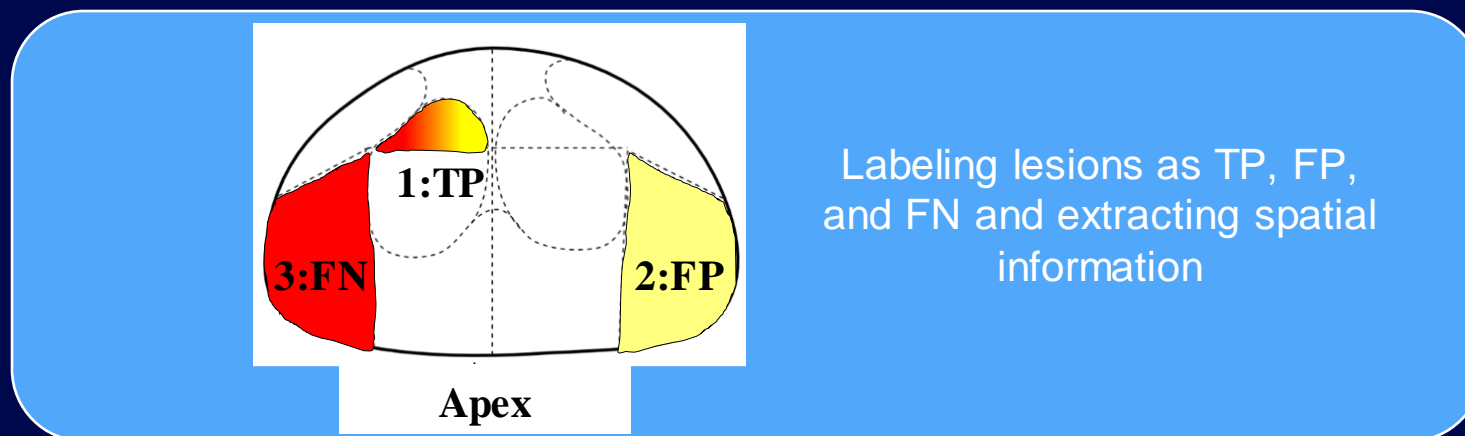


mpMRI

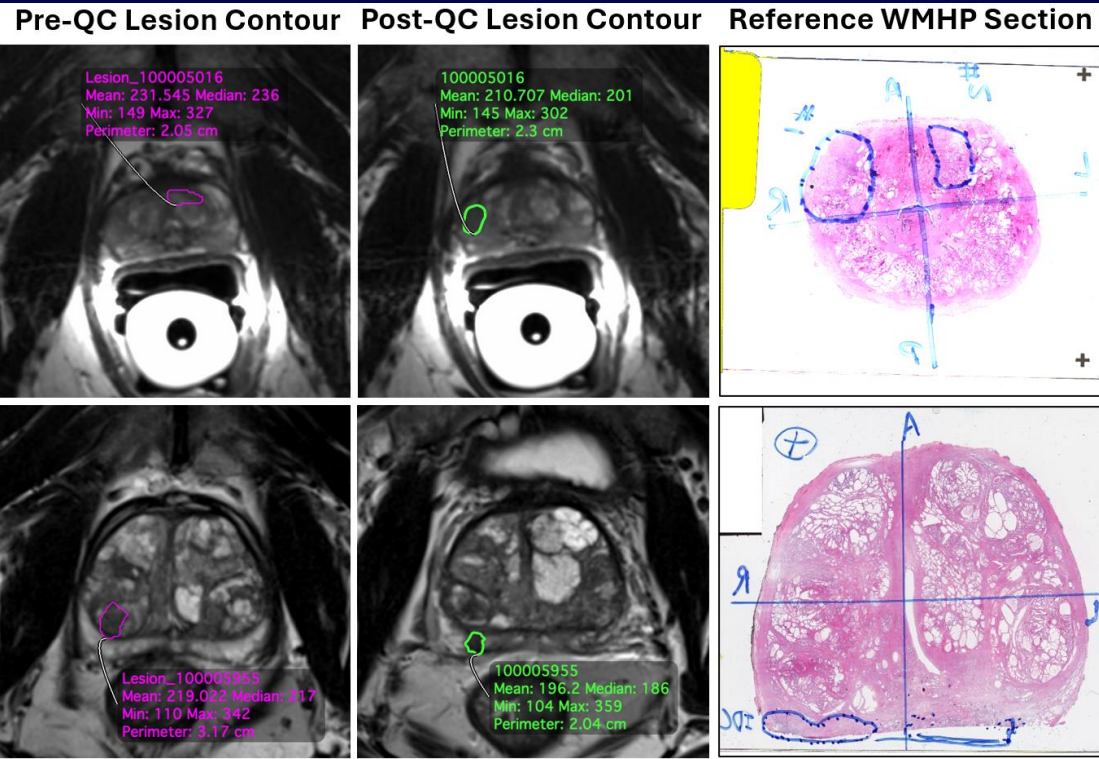
WMHP



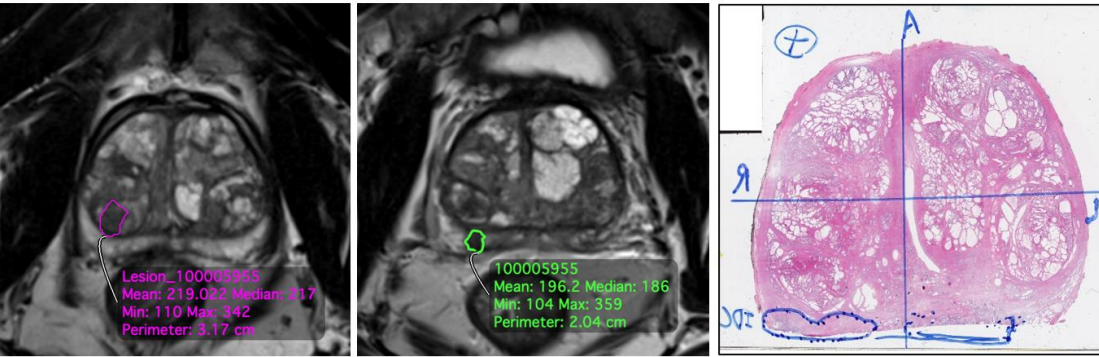
Radiology-pathology Correlation



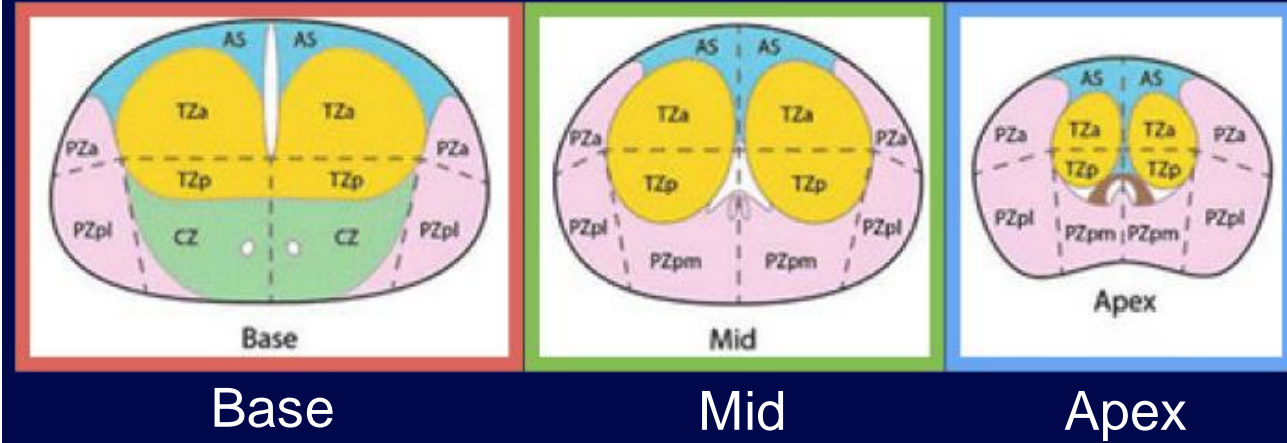
Example 1



Example 2



Prostate Sector Map (Standardized Prostate Segmentation)



Example	Research ID	Lesion ID	MRI Lesion Spatial Location	MRI Primary Lesion Location	Resection Lesion Spatial Location	Resection Primary Lesion Location
1	00OZMN8B	100005016	21,23	21	17,21,29,33	33
2	X27CB127	100005955	13	13	---	---
3	KXA7DRK6	100002321	26,38	26	24,26,36,38	24

BCHP-WMHP Correlation

- Maximum primary and secondary Gleason Scores from MR-US fusion biopsy and WMHP were collected from available pathology reports on electronic medical records
- Lesions were classified as being upgraded, downgraded, or isograded based on changes in Gleason Grade from BCHP to WMHP

Risk Group*	Grade Group	Gleason Score
Low/Very Low	Grade Group 1	Gleason Score ≤ 6
Intermediate (Favorable/Unfavorable)	Grade Group 2	Gleason Score 7 (3 + 4)
	Grade Group 3	Gleason Score 7 (4 + 3)
High/Very High	Grade Group 4	Gleason Score 8
	Grade Group 5	Gleason Score 9-10

BCHP-WMHP Correlation

- A total of 415 true positive lesions across 345 patients were identified
- 93 lesions were upgraded, 217 were isograded, and 105 were downgraded

Patient ID	MRI Lesion ID	MRI Lesion Spatial Location	MRI Primary Lesion Location	Gleason Score (BCHP)	Gleason Score (WMHP)	Classification (Upgrade, Downgrade, Isograde)
1_2N03RU22	100001929, 100001930	36, 38, 17	36, 17	3+3	3+4	Upgrade
1_8O3CN67R	10002265	26, 36, 38	38	4+4	3+4	Downgrade
1_55S8E392	100005759	11, 23	11	4+3	4+3	Isograde

Discussion

- Spatial Characterization Benefits for PCa
 - Improved precision sampling + targeting for tumor biopsies and thermal treatments
 - Can perform an integrated feature selection with clinical characteristics
 - Feature selection as prior information can refine clinical decision-making + AI-based diagnosis tools by improving PI-RADS performance
- BCHP-WMHP Correlation
 - Multi-scale mpMRI database allows us to directly assess the role of mpMRI parameters in upgrading from BCHP to WMHP

Highlights and Future Work

- A structured multi-scale database for AI/ML research is constructed after thorough data QC:
 - The radiology-pathology cohort includes mpMRI scans, lesion annotations, and a spreadsheet of spatial location characteristics (n=915)
 - The BCHP-WMHP cohort includes mpMRI scans, lesion annotation, and a spreadsheet of spatial location characteristics and histology mismatching (n=345)
- A manuscript describing all the detailed information is in preparation
- Institutional data release approval is in progress

Acknowledgements

PI




Kyung Sung,
Ph.D.

Postdoc




Kai
Zhao, Ph.D.

Ph.D. Students



Haoxin
Zheng, M.S.



Ran
Yan, M.S.



Alex
Hung, M.S.



Sohaib
Naim, M.S.



Kaifeng
Pang



Raymi
Ramirez



Dieter R. Enzmann, M.D.

Chair of Department of
Radiological Sciences

Ph.D. Students



Katarina
Chiam



Mimi
Li



Brian
Chau



Parsa
Hajipour



Hetvi
Trivedi



Khang
Doan

Visiting Scholar



Eunsun
Oh, M.D.

Study Coordinator



Nashla
Barroso

Funding Support:

- NIH R01 CA248506 (PIs: Sung / Wu)
- NIH R01 CA248506-S1 (PI: Sung / Wu)
- NIH R01 CA272702 (PI: Sung / Kim)
- NIH R01 CA272702-S1 (PI: Sung / Kim)
- UCLA Radiology

Collaborators

- Steven Raman, M.D.
- Robert Reiter, M.D.
- Leonard Marks, M.D.
- Wayne Brisbane, M.D.
- Anthony Sisk, D.O.

- David Lu, M.D.
- Holden Wu, Ph.D.
- William Hsu, Ph.D.
- Jason Chiang, M.D. / Ph.D.